



Ectopic thyroid with colloid Goitre presenting as submandibular swelling: A case report

Chinglaiphaba Chongtham¹, Sapam Opendro Singh², Chetan Maibam³, Sridartha Khumukcham⁴, Th. Sudhir Chandra Singh⁵

1. Postgraduate trainee 2. Assistant Professor 3& 4. Senior Registrar 5. Professor, Department of General Surgery, RIMS, Imphal, Manipur.

Submission Date: 01-11-2014

Acceptance Date: 11-11-2014

How to cite this article:

Vancouver/ICMJE Style

Chongtham C, Singh SO, MaibamC, KhumukchamC, Singh TSC. Ectopic thyroid with colloid Goitre presenting as submandibular swelling: A case report. *Int J Res Health Sci* [Internet]. 2015;3(1):38-41. Available from <http://www.ijrhs.com/issues.php?val=Volume3&iss=Issue1>

Harvard style

Chongtham, C., Singh, S.O., Maibam, C., Khumukcham, C., Singh, T.S.C. Ectopic thyroid with colloid Goitre presenting as submandibular swelling: A case report. *Int J Res Health Sci*. [Online] 3(1). p.38-41. Available from: <http://www.ijrhs.com/issues.php?val=Volume3&iss=Issue1>

Corresponding Author:

Dr. Chinglaiphaba Chongtham, PG Gents hostel 1, Room 35, Regional Institute of Medical Sciences, Imphal, Manipur.

Email: chinglaiphaba@gmail.com

Abstract:

Although rare, the presence of ectopic thyroid in submandibular region should be considered in the differential diagnosis of submandibular swelling. Defects in the embryological development, implantation of thyroid fragments and abnormal migration of the thyroid gland usually results in this ectopic presentation. The ectopic thyroid is predisposed to a spectrum of inflammatory and neoplastic changes similar to that of a normal thyroid. Diagnosis is confirmed by fine needle aspiration cytology and malignancy is excluded by histopathological examination. Surgical treatment depends on the presence of a normal functioning thyroid. A rare case of ectopic thyroid with colloid goitre in the left submandibular region is reported.

Key words: Colloid goitre, ectopic thyroid, lateral aberrant thyroid

Introduction:

Embryologically the thyroid gland is derived from a large median anlage and two lateral anlages [1]. Failure of the descent of median anlage results in a lingual thyroid. In some rare cases, the lack of fusion of the lateral anlage with median anlage results in lateral ectopic thyroid [2]. Diseases that affect a normal thyroid gland can also affect the ectopic tissue, but benign or malignant neoplastic transformation that affects the ectopic thyroid tissue is very rare. We report a case of colloid goitre of

ectopic submandibular thyroid in a person with normal orthotopic thyroid gland [3].

Case Report

A 58year old male presented to Department of Surgery at Regional Institute of Medical Sciences (RIMS), Imphal with a history of painless swelling in left upper region of the neck for the past 4years. There was no difficulty in swallowing or breathing. There was no clinical feature suggestive of hypo/hyperthyroidism.

On physical examination, mobile, painless, cystic swelling was located in the left submandibular region which was 5cm × 4cm in size (Figure.1). CECT of neck shows complex cystic space occupying lesion in left submandibular region with normal thyroid gland (Figure. 2). A fine-needle aspiration cytology showed occasional thyroid follicular epithelial cells with a few scattered cyst macrophages in a clear background suggestive of colloid goitre with cystic degeneration. Thyroid function test was found normal.

Surgical excision of the lesion was done. An encapsulated cystic swelling measuring 5cm×4cm×3cm was dissected and resected. No connection was present with the normal thyroid gland.

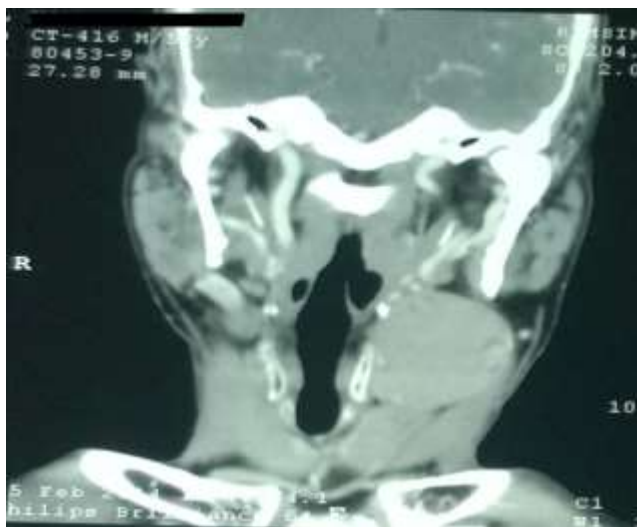
Histopathological examination showed features of colloid goitre with cystic degeneration. Thyroid tissue displayed numerous colloid filled follicles of varying sizes arranged in lobules and separated by thin septae. Intervening fibroconnective tissue showed few haemosiderin laden macrophages. Capsular and vascular invasion were not observed (Figure. 3).

Written consent was taken from the patient for publishing this case.

Figure 1: Photograph of patient showing swelling in left submandibular region

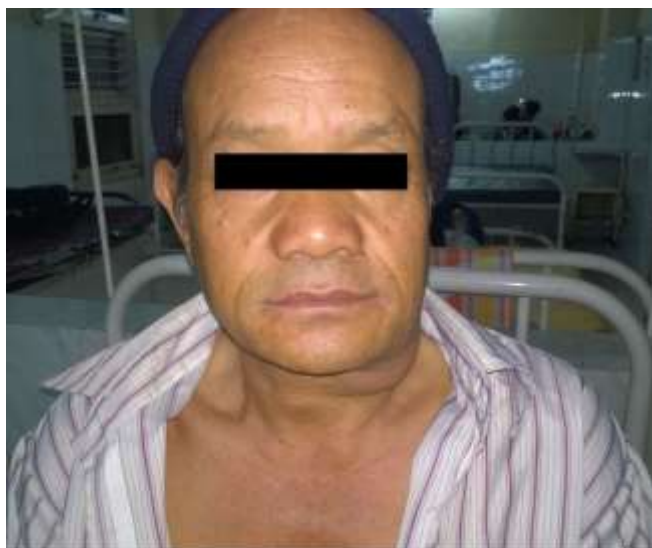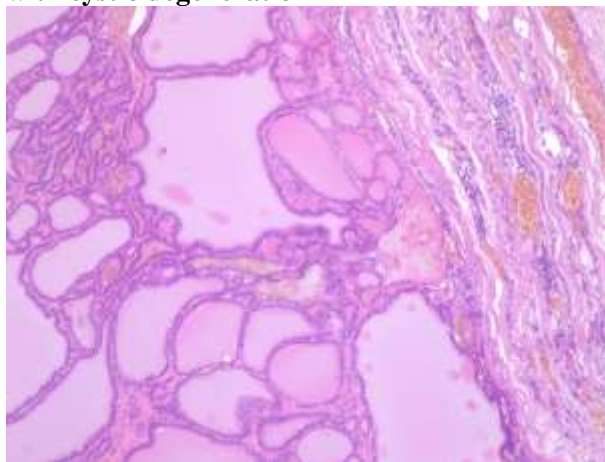


Figure 2: CECT of neck showing complex cystic space occupying lesion in left submandibular region with normal thyroid gland



The patient was discharged on the eighth postoperative day. Postoperative period was uneventful. Follow up was done for six months. No postoperative complication developed during this period.

Figure 3: Photomicrograph of the submandibular swelling 10× magnification showing colloid goitre with cystic degeneration



Discussion

Ectopic thyroid is defined as thyroid tissue not present anterolateral to second to fourth tracheal cartilages [4]. It is very rare with a prevalence of approximately 1 in 100000 to 300000 in the population with a female to male ratio of about 4:1 [5]. Ectopic thyroid are mostly located in the midline along the thyroglossal duct path. Ninety

percent of ectopic thyroids are at the base of the tongue, so called lingual thyroid [6]. Rarely, ectopic thyroid gland may present lateral to midline [7]. Only a few cases of ectopic thyroid gland in submandibular region have been reported. Presence of ectopic thyroid in submandibular space and a functional orthotopic thyroid gland is rarely reported in literature [4, 8-14].

Ectopic submandibular thyroid gland in the absence of an orthotopic thyroid gland may result from a dysembryoplasia of the lateral anlage, with lack of migration and agenesis of the median anlage [8]. If ectopic thyroid tissue exists next to an orthotopic thyroid gland, the ectopic thyroid tissue might be a portion of a nodular goitre displaced laterally due to the movement of neck muscles [14]. Another hypothesis is that the thyroid tissue might be implanted and then grow in the lateral part of the neck after surgery or trauma. Our patient does not have any history of trauma or surgery on thyroid. Finally, it has been hypothesised that "benign" infiltration of lymph nodes by thyroid cells not representing metastatic diffusion might take place, [15] but evidence supporting this assumption is lacking.

Most experts agree that the large majority of cases previously called "lateral aberrant thyroid" are in fact metastasis of thyroid primary carcinomas [10]. However, recent reports showed the presence of normal thyroid ectopic tissue in these supposed "aberrant tumours" [3].

Kanaya et al [12] reported ectopic thyroid tissue with partial adenomatous goitre in a 53-year-old woman who underwent subtotal thyroidectomy 30 years earlier. In our case, patient had colloid goitre of the ectopic thyroid in the presence of a normal thyroid gland.

Although rare, ectopic thyroid should be considered as a differential diagnosis of submandibular mass [4, 8-14]. In the submandibular region, ectopias are clinically indistinguishable from other pathologies, such as tumours of the salivary glands or cysts. In addition to clinical history and physical examination, ultrasonography and fine needle aspiration cytology are also useful for initial assessment [13].

Diagnostic and therapeutic difficulties may occur when only the ectopic tissue is functional (up to 70% of cases). Identification of presence or absence of eutopic thyroid gland should be considered for choosing the best treatment in these cases [9] since an inaccurate preoperative diagnosis can result in hypothyroidism [11].

Conclusion

Cases of ectopic thyroid, though rare, should be considered as a differential diagnosis of submandibular mass. Surgical resection and pathologic assessment represents the most appropriate therapeutic option because such lesions may harbour a primary cancer or metastases of hidden thyroid cancer.

Conflict of Interest: None

Source of Funding: Nil

Acknowledgement:

Authors acknowledge the immense help received from the scholars whose articles are cited and included in references of this manuscript. The authors are also grateful to authors/editors/publishers of all those articles, journals and books from where the literature for this article has been reviewed and discussed.

Source of Funding: Nil

Source of Conflict: None

References

1. Choi JY, Kim JH. A case of an ectopic thyroid gland at the lateral neck masquerading as a metastatic papillary thyroid carcinoma. *J Korean Med Sci.* 2008; 23(3):548-50.
2. Paresi RJ Jr, Saha D. Hashimoto's thyroiditis presenting as an enlarging submandibular mass in a patient with a lingual thyroid. *Otolaryngol Head Neck Surg* 2005; 132: 806-8.
3. Huang T-S, Chen H-Y. Dual thyroid ectopia with a normally located pretracheal thyroid gland: case report and literature review. *Head Neck* 2007; 29: 885-8. [PubMed: 17358039]
4. Damiano A, Glickman AB, Rubin JS, Cohen AF. Ectopic thyroid tissue presenting as a midline neck mass. *Int J Pediatr Otorhinolaryngol* 1996; 34: 141-8. [PubMed: 8770681]
5. Yeung VT, Loong EP, Cockram CS. Cretinism and lingual thyroid presenting in an adult. *Postgrad Med J* 1987; 63: 881-3. [PMCID: PMC2428619] [PubMed: 3447115]
6. Noyek AM, Friedberg J. Thyroglossal duct and ectopic thyroid disorders. *Otolaryngol Clin North Am* 1981; 14: 187-201. [PubMed: 7254840]
7. Feisal TKT, Prepageran N, Shahrizal T, Zulkiflee AB. Unusual parapharyngeal lesion: aberrant thyroid gland. *Singapore Med J* 2008; 49: e137-8. [PubMed: 18465039]

8. Kumar R, Sharma S, Marwah A, Moorthy D, Dhanwal D, Malhotra A. Ectopic goiter masquerading as submandibular gland swelling. A case report and review of the literature. *Clin Nucl Med* 2001; 26: 306–9. [PubMed: 11290889]
9. Zieren J, Paul M, Scharfenberg M, Menenakos C. Submandibular ectopic thyroid gland. *J Craniofac Surg* 2006; 17: 1194–8.
10. Sambola-Cabrer I, Fernández-Real JM, Ricart W, Barbas JF, Ollé M, Teruel J. Ectopic thyroid tissue presenting as a submandibular mass. *Head Neck* 1996; 18: 87–90. [PubMed: 8774926]
11. Aköz T, Erdogan B, Ayhan M, Cinar F. Ectopic submandibular thyroid tissue. *Rev Laryngol Otol Rhinol (Bord)* 1998; 119: 323–5. [PubMed: 10089802]
12. Kanaya H, Tanigaito Y, Shyono N, Hirabayashi H, Baba K. A rare case of ectopic, normally functioning thyroid tissue presenting as a left submandibular mass. *Nippon Jibiinkoka Gakkai Kaiho* 2005; 108: 850–3. [PubMed: 16218443]
13. Bersaneti JA, Silva RDP, Ramos RRN, Matsushita MM, Souto LRM. Ectopic Thyroid Presenting as a Submandibular Mass. *Head and Neck Pathol* 2011; 5:63-66.
14. Clay RC. Lateral aberrant thyroid: metastasis to lymph nodes from primary carcinoma of the thyroid gland. *Arch Surg* 1994; 48: 223–8.
15. Nicastri AD, Foote FW, Jr. Frazell EL. Benign thyroid inclusions in cervical lymph nodes. *JAMA* 1965; 194: 1–4. [PubMed: 5896935]